

# EXCESSIVE TIBIAL ROTATION IS RESTORED AFTER ANATOMICAL DOUBLE BUNDLE ANTERIOR CRUCIATE LIGAMENT RECONSTRUCTION

Mak-Ham Lam<sup>1,2</sup>, Daniel Tik-Pui Fong<sup>1,2</sup>, Patrick Shu-Hang Yung<sup>1,2</sup>,  
Eric Po-Yan Ho<sup>1,2</sup>, Kwai-Yau Fung<sup>1,3</sup>, Kai-Ming Chan<sup>1,2</sup>

Department of Orthopaedics and Traumatology, Prince of Wales Hospital, Faculty of  
Medicine, The Chinese University of Hong Kong, Hong Kong, China<sup>1</sup>  
The Hong Kong Jockey Club Sports Medicine and Health Sciences Centre, Faculty of  
Medicine, The Chinese University of Hong Kong, Hong Kong, China<sup>2</sup>  
Department of Orthopaedics and Traumatology, Alice Ho Miu Ling Nethersole  
Hospital, Hong Kong, China<sup>3</sup>

Recent studies suggested that tibial rotation was not restored after single bundle anterior cruciate ligament (ACL) reconstruction. This study aimed to determine if excessive tibial rotation would be restored by anatomical double bundle ACL reconstruction. Ten male subjects with unilateral ACL injury were prospectively assessed with a high demanding task before and after ACL reconstruction. Knee kinematics during pivoting movement was measured by a motion analysis system. The tibial rotation was reduced in the reconstructed knee after ACL reconstruction than the deficient knee ( $p < 0.05$ ). There was no difference on tibial rotation between intact knee and reconstructed knee. We concluded that the excessive tibial rotation in the deficient knee was restored after anatomical double bundle ACL reconstruction.

**KEYWORDS:** Sports medicine, ACL, rotational laxity, functional stability.

**INTRODUCTION:** Anterior cruciate ligament (ACL) injury leads to knee instability, mainly anterior-posterior (AP) and rotational direction. Clinically, the rotational laxity before and after ACL reconstruction is only examined with subjectively pivot shift test performed by orthopaedic surgeons, which is a combined movement of valgus and external rotation. The objective biomechanical way to evaluate functional rotational stability during high demanding movement is still not widely adopted in clinical setting.

Several kinematics studies, which intact knee was used as a control, investigated patients with unilateral ACL injury. On treadmill running, tibial rotation increased with speed in both injured and normal knees (Czerniecki et al., 1988). Waite and coworkers (2005) reported that low demand activity such as walking and running did not produce sufficient stress to initiate knee instability in ACL deficient knee. In a study to evaluate functional stability after ACL reconstruction, tibial rotation was found not to be restored after single bundle ACL reconstruction with hamstring graft during a pivoting movement (Georgoulis et al., 2007).

Optical motion analysis with reflective skin markers provided common and practical techniques for assessing kinematics of lower limb extremity. It was reported as a widely accepted, well-established and reliable gait analysis method (Chambers & Sutherland, 2002). The purpose of the current study was to investigate the range of tibial rotation of ACL deficient and reconstructed knees during a high demanding task. The contralateral intact knee was used as a control. We hypothesized that there would be a significant excessive tibial rotation in ACL deficient knee and this would be restored by anatomical double bundle ACL reconstruction.

**METHOD:** Ten male subjects (age =  $27.2 \pm 4.7$ yr, height =  $1.76 \pm 1.00$ m, body mass =  $69.1 \pm 9.2$ kg) with unilateral ACL injury were recruited in the study. ACL rupture was confirmed either by arthroscopy, magnetic resonance imaging or clinical examination. All subjects reported instability during sports and were suggested to have surgical treatment. All injuries were sport-related and all subjects participated at least one time per week of their sports before the injury. The university ethics committee approved the study. Informed consents were obtained from each subject before the study.

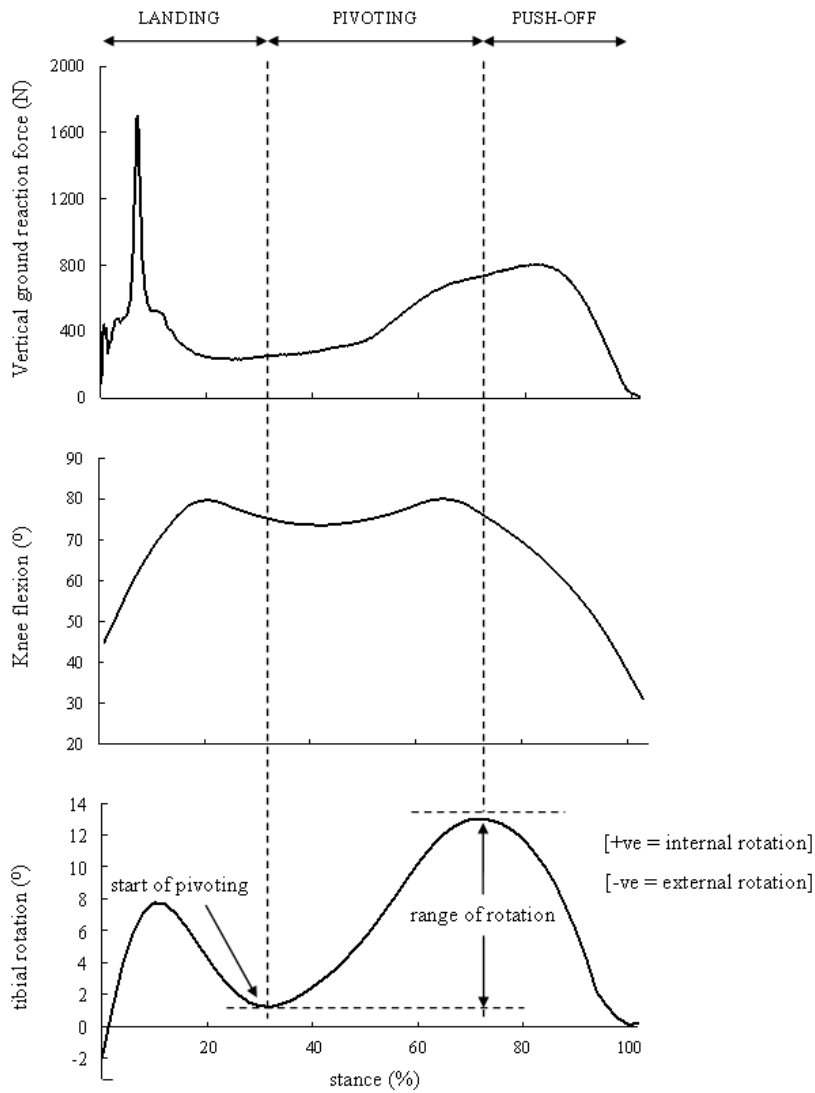
All subjects were assessed before and after anatomical double bundle ACL reconstruction with mean follow-up of  $329 \pm 187$  days. An optical motion analysis system with eight cameras (VICON, UK) was used to record three dimensional movements of lower extremities at 120Hz frequency. Synchronized force-plate (AMTI, USA) data was collected at the centre of the capture volume at 1080Hz. A fifteen-marker model (Davis et al., 1991) was adopted to collect lower limb kinematics during the movement. Skin reflective markers with 9mm diameter were placed at anatomical landmarks including anterior superior iliac spines, sacrum, greater trochanter, femoral epicondyle, tibial tubercle, lateral malleolus, heel and fifth metatarsal head on both limbs.

Before performing the movement, a standing trial was recorded for each subject in anatomical position. This calibration file provided a definition of zero degree for all segmental movements. Both deficient and intact knees were tested individually. The subjects were asked to jump from a 40cm-high platform and land with both feet on the ground, with only the testing foot on the force-plate. After the foot contact, the subjects pivoted 90 degrees to the lateral side of testing leg, which also acted as the core leg during pivoting. The subjects were instructed to run away after completing the pivoting movement. The evaluation period was defined from the first foot contact to the take-off of the testing leg on the ground. Three dimensional coordinates of every marker were exported from the VICON software. Together with the anthropometric measurements, the joint kinematics was then calculated (Davis et al., 1991). All calculations were conducted using self compiled program (MATLAB, USA). Force-plate was used to determine the evaluation period when the ground reaction force exceeded 5% of body mass. The main dependent variable in the current study was the range of tibial rotation angle during pivoting movement, which was a period defined from the lowest tibial internal rotation after landing to the highest tibial internal rotation (Ristanis et al., 2005). A paired t-test was employed to determine if statistically significant difference existed in range of tibial rotation between intact knee and deficient knee before reconstruction, between deficient knee and reconstructed knee, and between reconstructed knee and intact knee after reconstruction. Power analysis was also conducted if there was no significant difference between reconstructed knee and intact knee after reconstruction. The level of significance and study power were set at 0.05 and 0.8 respectively.

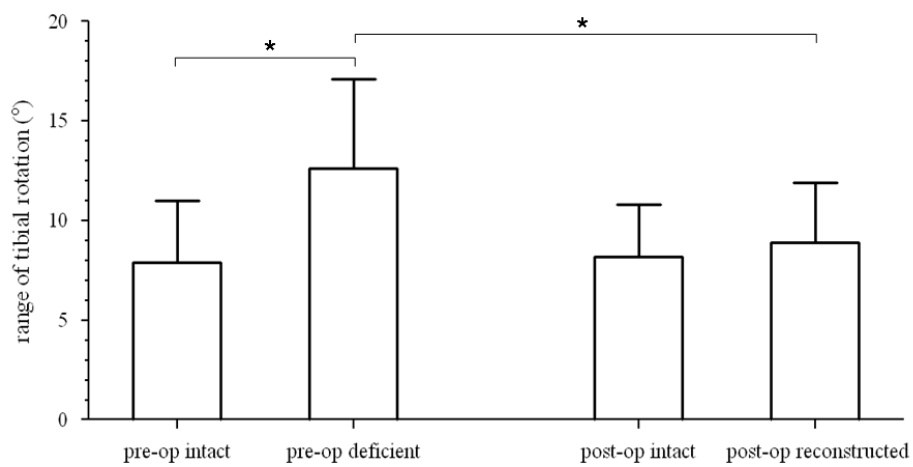
**RESULTS:** During the pivoting movement, the tibia internally rotated to a maximum degree (Figure 1). For the range of tibial rotation, there was a significant increase in the deficient knee ( $12.6 \pm 4.5$  degree) when compared to the intact knee ( $7.9 \pm 3.1$  degree) before reconstruction. This excessive tibial rotation significantly decreased to  $8.9 \pm 3.0$  degree for the reconstructed knee and did not differ to that of intact knee ( $8.2 \pm 2.6$  degree) after ACL reconstruction (Figure 2). Since there was no significant difference between reconstructed knee and intact knee after reconstruction, power analysis was conducted (true difference: 2 degrees; correlation: 0.27) and statistical power was reported to be 0.81 between the two groups.

**DISCUSSION:** In this study, the excessive tibial movement for ACL deficient knee and the reduction of this movement after ACL reconstruction were demonstrated. It was hypothesized that there would be a significant excessive tibial rotation on ACL deficient knee and it would be restored by anatomical double bundle ACL reconstruction. The result of the current study supported the first hypothesis. Moreover, the study power between both limbs after ACL reconstruction was above the pre-set value and so the second hypothesis was also supported in this study.

Our findings supported previous studies (Zaffagnini et al., 2000; Ristanis et al., 2005) that showed knee rotational laxity and instability of ACL deficient knee. In a swine study (Zaffagnini et al., 2000), the passive clinical internal-external knee rotation stress test was shown to give excessive laxity of ACL deficient knee when compared to intact knee. In another study (Ristanis et al., 2005) with similar protocol to the present study, the tibial



**Figure 1. Ground reaction force, flexion angle and tibial rotation during the entire stance phase of the high demanding task.**



**Figure 2. Range of tibial rotation during pivoting movement before and after ACL reconstruction. Asterisks (\*) indicate a significant difference.**

rotation of deficient knee was significantly higher than that of intact knee. While those subjects were instructed to walk followed by the pivoting movement, our subjects were instructed to run instead. We believed that the task in our study provided a higher rotational stress to the knee. Moreover, in our study, all the subjects were assessed prospectively before and after ACL reconstruction. The variations between study and control groups were limited to affect our result as intact knee was used as a control.

ACL reconstruction aims to reconstruct the original ACL with normal kinematics in both AP and rotational direction. However, in vitro (Woo et al., 2002) and in vivo (Georgoulis et al., 2007) studies showed that tibial rotation was not restored by single bundle ACL reconstruction. One of the reasons suggested that only anteromedial (AM) bundle was replicated, resulting in insufficient rotational control to the knee. In the current study, all subjects were treated with anatomical double bundle ACL reconstruction, in which both AM and posterolateral (PL) bundles were reconstructed to mimic the original ACL anatomy. In addition to the AM bundle, PL bundle provided an important role in the stabilization of the knee against a combined rotatory load (Gabriel et al., 2004). When evaluating double bundle ACL reconstruction with a high demanding activity, the significant decrease in range of tibial rotation of the reconstructed knee suggested the effectiveness of rotational control of PL bundle.

**CONCLUSION:** It was concluded that there was excessive tibial rotation in ACL deficient knee during a dynamic functional pivoting movement in this study. The reconstructed knee successfully improved functional knee rotational stability as demonstrated by the restoration of excessive tibial rotation during a pivoting movement before and after anatomical double bundle ACL reconstruction.

## REFERENCES:

- Chambers H.G. & Sutherland D.H. (2002). A practical guide to gait analysis. *Journal of the American Academy of Orthopaedic Surgeons*, 10, 222-231.
- Czerniecki J.M., Lippert F. & Olerud J.E. (1988). A biomechanical evaluation of tibiofemoral rotation in anterior cruciate deficient knees during walking and running. *American Journal of Sports Medicine*, 16(4), 327-331.
- Davis R.B., Ounpuu S., Tyburski D. & Gage J.R. (1991). A gait analysis data collection and reduction technique. *Human Movement Science*, 10(5), 575-587.
- Gabriel M.T., Wong E.K., Woo S.L., Yagi M. & Debski R.E. (2004). Distribution of in situ forces in the anterior cruciate ligament in response to rotatory loads. *Journal of Orthopaedic Research*, 22(1), 85-89.
- Georgoulis A.D., Ristanis S., Chouliaras V., Moraiti C. & Stergiou N. (2007). Tibial rotation is not restored after ACL reconstruction with a hamstring graft. *Clinical Orthopaedics and Related Research*, 454, 89-94.
- Ristanis S., Stergiou N., Patras K., Vasiliadis H., Giakas G. & Georgoulis A.D. (2005). Excessive Tibial rotation during high-demand activities is not restored by anterior cruciate ligament reconstruction. *Arthroscopy*, 21(11), 1323-1329.
- Waite J.C., Beard D.J., Dodd C.A., Murray D.W. & Gill H.S. (2005). In vivo kinematics of the ACL-deficient limb during running and cutting. *Knee Surgery Sports Traumatology Arthroscopy*, 13(5), 377-384.
- Woo S.L., Kanamori A., Zeminski J., Yagi M., Papageorgiou C. & Fu F.H. (2002). The effectiveness of reconstruction of the anterior cruciate ligament with hamstrings and patellar tendon: a cadaveric study comparing anterior tibial and rotational loads. *Journal of Bone and Joint Surgery (Am)*, 84, 907-914.
- Zaffagnini S., Martelli S., Falcioni B., Motta M. & Marcacci M. (2000). Rotational laxity after anterior cruciate ligament injury by kinematic evaluation of clinical tests. *Journal of Medical Engineering & Technology*, 24(5), 230-236.

## Acknowledgement

This research project was made possible by equipment/resources donated by The Hong Kong Jockey Club Charities Trust.